

# SURGICAL CORRECTION OF THE SNAPPING ILIOPSOAS TENDON IN ADOLESCENTS

BY MATTHEW B. DOBBS, MD, J. ERIC GORDON, MD, SCOTT J. LUHMANN, MD,  
DEBORAH A. SZYMANSKI, RN, AND PERRY L. SCHOENECKER, MD

*Investigation performed at Shriners Hospitals for Children, St. Louis Unit, and Saint Louis Children's Hospital, St. Louis, Missouri*

**Background:** There have been very few reports regarding symptomatic snapping of the iliopsoas tendon, and none of those reports have dealt exclusively with an adolescent population. We report our experience with the surgical treatment of this entity in a group of patients who had an average age of fifteen years.

**Methods:** Nine adolescent patients (eleven hips) underwent fractional lengthening of the iliopsoas tendon at the musculotendinous junction because of persistent painful snapping of the hip. A modified iliofemoral approach to the iliopsoas tendon was used. The diagnosis in all cases was made on the basis of the history and a physical examination. Plain radiographs were made for all patients to rule out an osseous intra-articular loose body. Follow-up consisted of personal interviews and physical examinations performed at least two years postoperatively.

**Results:** Preoperatively, all patients had audible snapping with pain localized to the anterior part of the groin. The average duration of symptoms was 2.3 years. Prior to the onset of symptoms, all but one of the patients had been involved in competitive athletic activities. Postoperatively, all patients were able to return to the preoperative level of activity without subjective weakness. The average duration of postoperative follow-up was four years. Hip-flexion strength was noted to be nearly equal to that on the contralateral side. All patients reported that they would have the operation again under similar circumstances. One patient had recurrent snapping but stated that it was less frequent and less painful than the preoperative snapping. Two patients had transient sensory loss in the anterolateral aspect of the thigh.

**Conclusions:** We conclude that fractional lengthening of the iliopsoas tendon at the musculotendinous junction is an effective and safe approach for adolescent patients with persistent symptomatic snapping of the iliopsoas tendon that is unresponsive to conservative measures.

Coxa saltans, or snapping hip, is characterized by an audible snapping that usually occurs with flexion and extension of the hip. This snapping can be accompanied by pain and often occurs during physical activity. It can be divided into three types: external, internal, and intra-articular, with the external type being by far the most common<sup>1</sup>. The external type is caused by snapping of either the posterior border of the iliotibial band or the anterior border of the gluteus maximus over the greater trochanter<sup>1-4</sup>. The internal type, which is still the most poorly understood, has a variety of presumed etiologies, with snapping of the iliopsoas tendon over the iliopectineal eminence<sup>5</sup> or over the femoral head<sup>4</sup> being the most common. The intra-articular type is caused by a loose body in the joint, such as a fracture fragment or a torn piece of labrum. It usually has a distinctive presentation and, unlike the other types of snapping, almost always requires surgery for symptomatic relief<sup>6,7</sup>.

The history and physical examination are usually diagnostic of the internal type of coxa saltans, with the patient describing a painful snapping sensation localized to the anterior part of the groin. However, because of its rarity, this type of snapping hip can present a formidable diagnostic challenge. The snapping can often be willfully reproduced by the patient in either the supine or the standing position. In addition, the examiner can frequently reproduce the snapping by having the patient lie supine and bringing the hip from a flexed and abducted position to an extended and adducted position (Figs. 1-A and 1-B). This is due to the iliopsoas tendon shifting from lateral to medial over the iliopectineal eminence<sup>5</sup> and/or the femoral head<sup>4</sup> when the hip is brought from flexion into extension.

There have been very few reports addressing the internal type of snapping hip<sup>1-5,8</sup>, and none of those reports have dealt exclusively with adolescents. We are aware of only one study in which the authors described a detailed surgical approach and technique for addressing the snapping iliopsoas tendon in patients who were unresponsive to nonoperative measures that

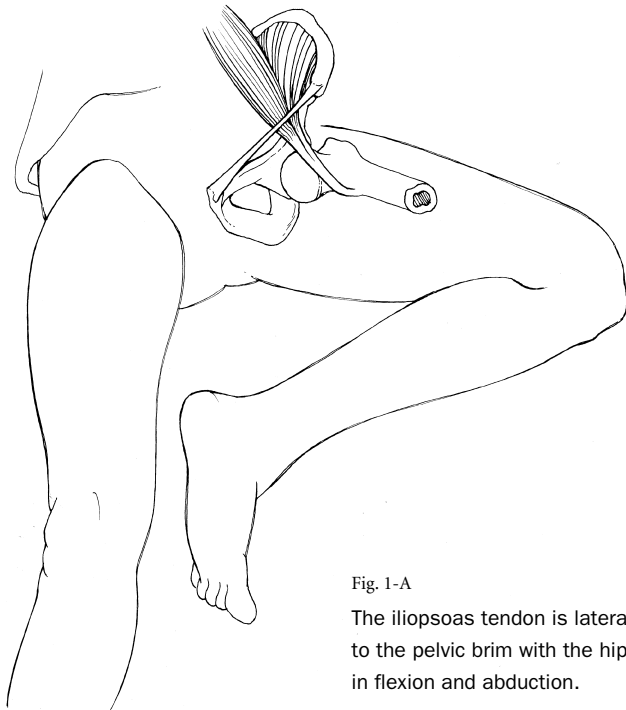


Fig. 1-A  
The iliopsoas tendon is lateral to the pelvic brim with the hip in flexion and abduction.

included rest, avoidance of activities that produced the snapping, and a six-to-eight-week physical therapy program emphasizing stretching of the iliopsoas tendon<sup>2</sup>. Those authors, however, also reported that substantial subjective weakness of hip flexion was noted postoperatively<sup>2</sup>.

The high prevalence of hip flexion weakness that has been reported after surgical treatment of the snapping iliopsoas tendon<sup>1,2</sup> led us to study our results of surgical treatment of this condition in a group of adolescent patients. Our surgical approach and our technique of lengthening the iliopsoas tendon differ from those reported in the literature<sup>1,2</sup>. We hypothesized that fractional lengthening of the tendon at the musculotendinous junction over the iliopectineal eminence would lead to less postoperative loss of hip-flexion strength. Therefore, we were specifically interested in assessing postoperative hip-flexion strength and the ability of the patients to return to the preoperative level of activity. In the present report, we describe our experience with nine adolescent patients (eleven hips) who were treated surgically for persistent, painful internal snapping of the hip that was unresponsive to nonoperative measures.

### Materials and Methods

Fifteen patients (seventeen hips) with a snapping hip and localized pain in the groin were evaluated at the Saint Louis Shriners Hospital and the St. Louis Children's Hospital over a ten-year period. All patients were diagnosed with iliopsoas snapping. There were three boys and twelve girls, and the average age of the patients was fifteen years. All patients complained of a generalized ache in the hip associated with an audible snap that occurred with extension of the flexed and ab-

ducted hip, and all were managed with decreased activity and guided iliopsoas-stretching exercises. Six patients (six hips) became asymptomatic after nonoperative treatment and did not require any additional intervention. The symptoms in the remaining nine patients (eleven hips) subsided but did not resolve, and this group of patients constituted the study population. The average duration of symptoms in these nine patients was 2.3 years (range, one to four years) (Table I). Eight patients had been involved in athletic and/or aerobic activities prior to the onset of symptoms. A specific event typically precipitated the symptoms; the most common precipitating activities were sprinting and long-distance running. In all cases, pain associated with snapping inhibited participation in sports activities.

The physical examination was similar in all patients. In six patients, the examiner was able to reproduce an audible snap by moving the hip from flexion to extension. In the other three patients, the snapping could only be reproduced by moving the hip from a position of flexion and abduction to a position of extension and adduction as described by Allen and Cope<sup>1</sup> (Figs. 1-A and 1-B). Pain was localized to the groin and coincided with the snapping. There was no palpable slipping of the ilio-tibial band or the gluteus maximus over the greater trochanter.

All but one of the patients had normal radiographic findings. The remaining patient had radiographic evidence of calcification in the region of the iliopsoas tendon. Two patients underwent iliopsoas bursography in an attempt to demonstrate snapping of the iliopsoas tendon. Three patients had had magnetic resonance imaging of the hip before referral to

Fig. 1-B  
Snapping is reproduced as the tendon moves to a more medial position on the pelvic brim with extension and adduction of the hip.

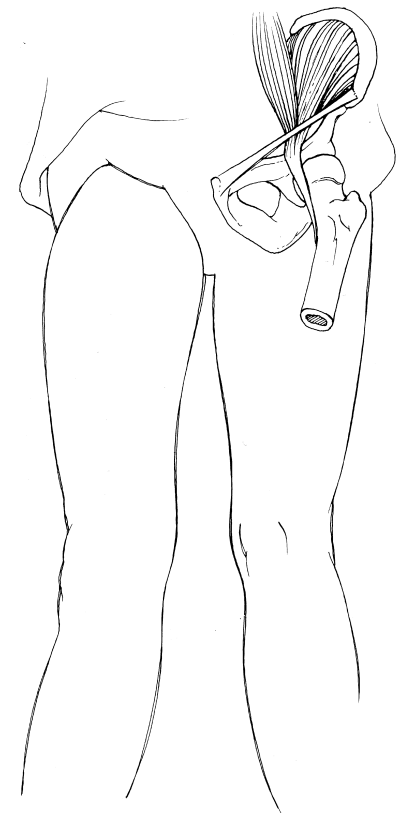


TABLE I Data on the Patients

Case	Age (yr)	Gender	Duration of Symptoms (yr)	Side of Involvement	Precipitating Activity	Diagnosis Before Referral
1	14	F	3	Bilateral	Walking	"Sprained hip"
2	15	F	4	Left	Rollerblading	Acetabular dysplasia
3	16	F	2	Right	Walking	Aseptic necrosis
4	14	F	3	Bilateral	Jogging	Iliotibial band snapping
5	15	M	2	Right	Sprinting	Herniated disc
6	16	M	2	Left	Sprinting	Labral tear
7	15	F	2	Left	Cross-country running	Herniated disc
8	15	F	2	Left	Cross-country running	Iliotibial band snapping
9	17	F	1	Left	Sprinting	Iliotibial band snapping

our institution to rule out intra-articular abnormalities.

Before referral to our institution, all patients had undergone various treatment modalities, including physical therapy emphasizing iliopsoas stretching, nonsteroidal anti-inflammatory medications, and modification of activity. None of the patients had been diagnosed accurately before referral. Two had had an extensive evaluation for a presumed herniated disc. Another two had had release of the iliotibial band because of a presumed diagnosis of iliotibial band snapping. After referral to our institution, all patients underwent a supervised physical therapy program emphasizing iliopsoas stretching for a minimum of three months.

#### Operative Procedure

The patient is positioned supine on the operating table, and general anesthesia is administered. To facilitate identification of the iliopsoas tendon later in the procedure, no paralyzing anesthetic agents are administered as the operation proceeds. After the operative site is prepared and draped in a sterile fashion, an oblique incision is made parallel to, but one fingerbreadth below, the iliac crest. The incision begins 1 cm distal to the anterior superior iliac spine and extends proximally for a distance of 6 to 7 cm (Fig. 2-A). The fascia of the tensor fasciae latae is incised, and scissor dissection is carried medially over this muscle and readily into the interval between it and the sartorius. This approach protects the lateral femoral cutaneous nerve, which lies medial to the plane of dissection.

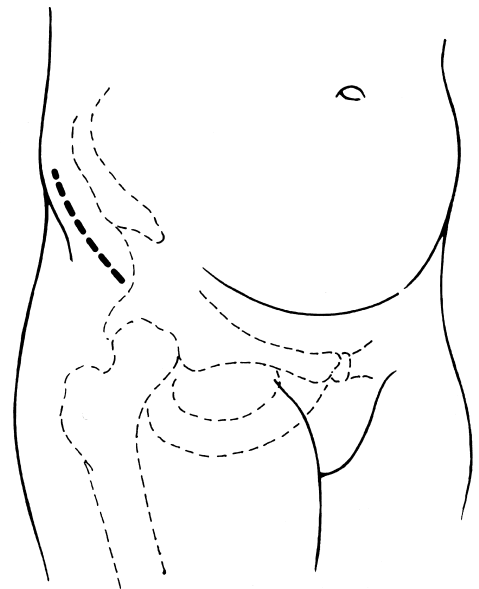
The fascia and the most inferior lateral fibers of the external oblique muscle are then dissected off the iliac apophysis with electrocautery and preserved for closure. The interval between the sartorius and the tensor fasciae latae is further developed by blunt dissection in order to effectively pull the sartorius muscle medially. The rectus femoris muscle is identified on the floor of this interval but is left intact. The iliac apophysis is sharply split with a knife down to bone (Fig. 2-B). The sartorius and iliopsoas muscles can then be dissected medially along with the attached portion of apophyseal cartilage. In a skeletally mature patient, the sartorius and iliopsoas muscles are dissected off the iliac crest along with a small portion of il-

iac crest bone. The iliopsoas muscle is further dissected subperiosteally off the inner side of the ilium, extending from the anterior superior iliac spine proximally for a distance of about 6 cm. Distally, the interval between the rectus femoris laterally and the iliopsoas medially is developed after incision of the fascia of the iliopsoas muscle.

With the hip flexed, the iliopsoas tendon can be palpated distally on the underside of the muscle. The tendon sheath is directly visualized and sharply incised. Care is taken to identify the tendon because the femoral nerve lies nearby and can be confused with it. To be sure that the nerve is not mistaken for the tendon, very low-level electrocautery is applied to it prior to lengthening. Should this cause any muscular activity in the thigh, additional dissection is carried out to clearly distinguish the tendon from the femoral nerve. Once the tendon has been clearly identified, it is fractionally lengthened at the musculotendinous junction. All identifiable tendon fibers at this level are transected. The hip is then moved

Fig. 2-A

The surgical incision (heavy dotted line) starts one fingerbreadth below the iliac crest and 1 cm distal to the anterior superior iliac spine. The incision extends proximally for a distance of 6 to 7 cm.



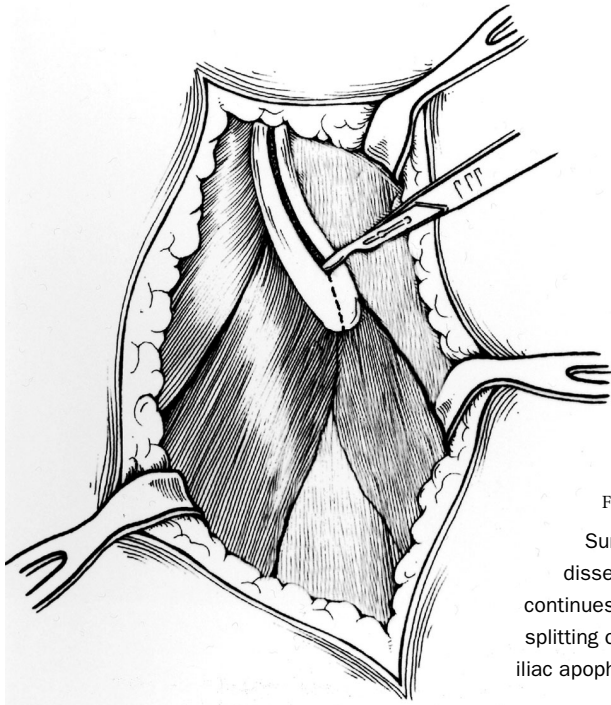


Fig. 2-B  
Surgical  
dissection  
continues with  
splitting of the  
iliac apophysis.

through a range of motion while the iliopsoas muscle is palpated. Any additional tendon fibers are first visualized and then transected. The sartorius muscle and the attached iliac apophysis or crest are reattached to the ilium. The external oblique muscle is closed, the subcutaneous tissues are closed, and finally the skin is closed in a subcuticular fashion.

Postoperatively, the patient uses crutches for weight-bearing as tolerated. Full weight-bearing is usually achieved by two weeks. Range-of-motion exercises are started at three weeks, and strengthening exercises are begun at approximately six weeks. All patients were seen at a minimum of one year postoperatively, at which time manual testing of the strength of the hip flexors was performed by the same physical thera-

pist and by one of us (M.B.D.). The patient was seated in a chair and asked to lift the knee toward the ceiling against resistance applied by the examiner. Comparison with the normal side was done in cases of unilateral involvement.

### Results

All nine patients (eleven hips) were followed for a minimum of two years (average, four years). One patient had a recurrence of snapping but stated that the symptoms were much less frequent and severe than they had been preoperatively. All patients returned to their preoperative level of activity, which involved competitive athletics in all cases but one. All patients noted that they were better as a result of the procedure and stated that they would have the operation again under similar circumstances. No patient had a detectable loss of hip-flexion strength. Two patients had a transient decrease in sensation that was localized to the anterolateral aspect of the thigh (Table II).

### Discussion

Most reports of painful snapping about the hip have dealt with the external type, which is by far the most common<sup>2-5,9,10</sup>. Less commonly, patients present with a painful snapping localized to the anterior part of the groin that can be attributed to the iliopsoas tendon. This internal type of coxa saltans was first reported in 1951<sup>5</sup>. The cause of this condition was believed to be snapping of the iliopsoas tendon over the iliopectineal eminence. Two of the three patients in the initial report had good relief after iliopsoas lengthening. Other reported causes of internal snapping include snapping of the iliopsoas over an exostosis of the lesser trochanter<sup>4</sup>, snapping attributed to the iliopsoas bursa<sup>11</sup>, and snapping due to habitual dislocation of the hip<sup>12</sup>.

Snapping of the iliopsoas tendon is a poorly recognized entity, as evidenced by the fact that all of the patients in the present study had had an incorrect diagnosis prior to referral (Table I). Once recognized, the reproducible painful snap of the iliopsoas can be palpated anteriorly and medially over the affected hip. As this finding is pathognomonic for the condition,

TABLE II Results of Surgical Treatment with Fractional Lengthening of the Iliopsoas Tendon

Case	Recurrence of Snapping	Hip-Flexion Strength on Affected Side ( <i>grade</i> )	Return to Activities that Precipitated Symptoms	Complications	Duration of Follow-up (yr)
1	No	5/5 (bilat.)	Yes	None	2
2	No	5/5	Yes	None	2
3	No	5/5	Yes	None	4
4	No	5/5 (bilat.)	Yes	Transient anterolateral thigh numbness	10
5	Yes	5/5	Yes	None	6
6	No	5/5	Yes	None	2
7	No	5/5	Yes	Transient anterolateral thigh numbness	3
8	No	5/5	Yes	None	5
9	No	5/5	Yes	None	2

we have found imaging tests to be unnecessary. In most cases, the snapping can be reproduced by simply moving the hip from flexion to extension with the patient lying supine. However, in some cases, it is necessary to move the hip from flexion and abduction to extension and adduction in order to reproduce the snapping. In either situation, the snapping is thought to be due to the iliopsoas tendon's moving from a lateral position on either the iliopectineal eminence or the femoral head when the hip is in flexion to a more medial position as the hip is extended.

Early studies involving the use of iliopsoas bursography suggested that the snapping was most likely caused by the back-and-forth motion of the iliopsoas tendon passing over the femoral head rather than over the iliopectineal eminence<sup>4,12</sup>. However, one of the limitations of bursography is that the tendon itself is not injected and is therefore only visualized indirectly as a negative defect impressing upon the bursa.

In 1988, Staple et al.<sup>13</sup> used tenography to demonstrate snapping of the iliopsoas tendon over the iliopectineal eminence. This technique involves injecting the tendon itself with contrast material and then observing its movement under fluoroscopic examination. Unlike bursography, this technique allows direct visualization of the tendon. Although tenography has been useful in furthering our understanding of the etiology of the snapping, it is not necessary for clinical diagnosis. In the present study, intraoperative palpation revealed the iliopsoas tendon to be tight over the iliopectineal eminence when the hip was moved from flexion to extension. Fractional lengthening at the musculotendinous junction successfully relieved the symptoms in all patients.

In 1990, Jacobson and Allen<sup>2</sup> reported on eighteen patients (twenty hips) who had iliopsoas lengthening because of persistent, painful internal snapping. The average age of the patients was twenty-three years, and the average duration of follow-up was twenty-five months. Six patients had recurrent snapping, and two of them had a reoperation. Three patients reported subjective weakness of the hip flexors, although none of them had objective testing. The operation was performed through a groin incision paralleling the inguinal crease. The technique described by those authors involves cutting through 50% of the tendon distally near its insertion on the lesser trochanter. An additional three or four cuts are made in the tendon slightly more proxi-

mally. When the musculotendinous portion of the muscle is reached, the tendinous portion is entirely released.

In contrast to that technique, our use of a modified iliofemoral approach, although relatively extensive, allows excellent visualization of the iliopsoas musculotendinous junction and facilitates complete transection of all tendon fibers at this level. Extreme caution should be taken to correctly identify the tendon before transection because the femoral nerve lies nearby. To minimize the risk of injury of the femoral nerve, we make sure that no paralyzing agents are administered to the patient during the procedure and we use very low-level electrocautery to stimulate the tendon before cutting its fibers to ensure that nerve fibers are not included. Care should also be taken to avoid injury to the lateral femoral cutaneous nerve, as two of our patients had transient numbness in the anterior part of the thigh that presumably was caused by traction on this nerve. The nerve should be identified on the sartorius side of the sartorius-tensor muscle interval and retracted medially. The results of the present study suggest that our method of fractional lengthening of the iliopsoas tendon at the musculotendinous junction is effective for relieving symptoms and allowing patients to return to their preoperative level of function while preserving hip-flexion strength. ■

Matthew B. Dobbs, MD

J. Eric Gordon, MD

Scott J. Luhmann, MD

Perry L. Schoenecker, MD

Department of Orthopaedic Surgery, Saint Louis Children's Hospital, Washington University School of Medicine, One Children's Place, St. Louis, MO 63110. E-mail address for M.B. Dobbs: dobbsmatthew@hotmail.com

Deborah A. Szymanski, RN

Shriners Hospitals for Children, 2001 S. Lindbergh Boulevard, St. Louis, MO 63131

The authors did not receive grants or outside funding in support of their research or preparation of this manuscript. They did not receive payments or other benefits or a commitment or agreement to provide such benefits from a commercial entity. No commercial entity paid or directed, or agreed to pay or direct, any benefits to any research fund, foundation, educational institution, or other charitable or nonprofit organization with which the authors are affiliated or associated.

## References

1. **Allen WC, Cope R.** Coxa Saltans: the snapping hip revisited. *J Am Acad Orthop Surg.* 1995;3:303-8.
2. **Jacobson T, Allen WC.** Surgical correction of the snapping iliopsoas tendon. *Am J Sports Med.* 1990;18:470-4.
3. **Mayer L.** Snapping hip. *Surg Gynecol Obstet.* 1919;29:425-8.
4. **Schaberg JE, Harper MC, Allen WC.** The snapping hip syndrome. *Am J Sports Med.* 1984;12:361-5.
5. **Nunziata A, Blumenfeld I.** Cadera a resorte: A proposito de una variedad. *Prensa Med Argent.* 1951;38:1197-2001.
6. **Ikeda T, Awaya G, Suzuki S, Okada Y, Tada H.** Torn acetabular labrum in young patients. Arthroscopic diagnosis and management. *J Bone Joint Surg Br.* 1988;70:13-6.
7. **Suzuki S, Awaya G, Okada Y, Maekawa M, Ikeda T, Tada H.** Arthroscopic diagnosis of ruptured acetabular labrum. *Acta Orthop Scand.* 1986;57:513-5.
8. **Lyons JC, Peterson LF.** The snapping iliopsoas tendon. *Mayo Clin Proc.* 1984;59:327-9.
9. **Brignall CG, Stainsby GD.** The snapping hip. Treatment by Z-plasty. *J Bone Joint Surg Br.* 1991;73:253-4.
10. **Zoltan DJ, Clancy WG Jr, Keene JS.** A new operative approach to snapping hip and refractory trochanteric bursitis in athletes. *Am J Sports Med.* 1986;14:201-4.
11. **Harper MC, Schaberg JE, Allen WC.** Primary iliopsoas bursography in the diagnosis of disorders of the hip. *Clin Orthop.* 1987;221:238-41.
12. **Stuart PR, Epstein HP.** Habitual hip dislocation. *J Pediatr Orthop.* 1991; 11:541-2.
13. **Staple TW, Jung D, Mork A.** Snapping tendon syndrome: hip tenography with fluoroscopic monitoring. *Radiology.* 1988;166:873-4.