

SUBSPECIALTY PROCEDURES

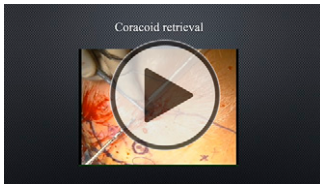
THE CUISTOW: A MODIFIED ARTHROSCOPIC BRISTOW PROCEDURE FOR THE TREATMENT OF RECURRENT ANTERIOR SHOULDER INSTABILITY

Lin Lin, MD, PhD, Hao Luo, MD, Xu Cheng, MD, Hui Yan, MD, Guoqing Cui, MD

Published outcomes of this procedure can be found at: *J Bone Joint Surg Am.* 2021 Jan 6; 103(1):15-22.

Investigation performed at the Institute of Sports Medicine, Peking University Third Hospital, Beijing, People's Republic of China

COPYRIGHT © 2022 THE AUTHORS. PUBLISHED BY THE JOURNAL OF BONE AND JOINT SURGERY, INCORPORATED. ALL RIGHTS RESERVED



Click the arrow above or go to surgicaltechniques.jbjs.org to view the video article described in this summary.

Abstract

Background: The rate of nonunion observed among the variety of Bristow-Latarjet procedures reportedly ranges from 9.4% to 28%¹. In Chinese timber buildings, the mortise-tenon joint is commonly utilized to connect beams to columns. Drawing inspirations from this concept, we created a bone trough in the glenoid neck to serve as a mortise and trimmed the coracoid graft to serve as a tenon, then fixed this mortise-tenon joint with a metal screw. Compared with a standard Bristow-Latarjet procedure, the key feature of this technique was that the coracoid process was placed into a trough (5 to 10 mm deep) in the glenoid neck, which substantially increased the bone contact area between the graft and glenoid neck. We called this surgical technique the Chinese unique inlay Bristow (Cuistow).

Description: Specific instruments have been designed to improve the safety and accuracy of the arthroscopic inlay Bristow procedure (Weigao, Shangdong, China). The posterior portal (A), superolateral portal (B), and 3 anterior portals (i.e., proximal [C], inferolateral [D], and inferomedial [E]) were utilized. General anesthesia and an interscalene block were administered with the patient in the beach-chair position. The surgical technique can be divided into 6 steps: (1) evaluation of the shoulder joint; (2) coracoid preparation, drilling, and osteotomy; (3) subscapularis splitting and labrum detachment; (4) glenoid preparation and drilling; (5) coracoid retrieval, trimming, transfer, and fixation; and (6) Bankart repair.

Alternatives: Soft-tissue capsulolabral repairs or bone reconstruction procedures are commonly performed for the treatment of anterior glenohumeral instability². The arthroscopic Bristow-Latarjet procedure is increasingly popular for the treatment of anterior shoulder instability with a substantial osseous defect of the glenoid³. Defects that are too large to be restored with the coracoid process can be treated with use of the Eden-Hybbinette procedure or a distal tibial allograft^{4,5}.

Rationale: This procedure was inspired by the structure of mortise-tenon joints, resulting in a modified version of the Bristow-Latarjet technique in

Disclosure: The Disclosure of Potential Conflicts of Interest forms are provided with the online version of the article (<http://links.lww.com/JBJS/ST/A364>).

Copyright © 2022 The Authors. Published by The Journal of Bone and Joint Surgery, Incorporated. All rights reserved. This is an open-access article distributed under the terms of the [Creative Commons Attribution-Non Commercial-No Derivatives License 4.0](https://creativecommons.org/licenses/by-nc-nd/4.0/) (CCBY-NC-ND), where it is permissible to download and share the work provided it is properly cited. The work cannot be changed in any way or used commercially without permission from the journal.

which the coracoid process is trimmed and placed into a trough (5 to 10 mm deep) in the glenoid neck. This procedure substantially increases the contact area between the fresh bone surface and the coracoid and glenoid neck. Another important advantage of this technique is that it can facilitate accurate positioning of the coracoid on the glenoid. This procedure resulted in a high rate of graft healing, excellent functional outcomes (Rowe and American Shoulder and Elbow Surgeons Shoulder scores), and a high rate of return to sport⁶. Currently, indications of this procedure are (1) participation in high-demand sports (i.e., collision and overhead) combined with the presence of a glenoid defect involving <25% of the glenoid, or (2) any glenoid defect involving 10% to 25% of the glenoid.

Expected Outcomes: Increased bone-contact area and accurate positioning of the graft helped to facilitate osseous union, with a union rate of 96.1% at 12 months postoperatively. The clinical outcomes were excellent, with a high rate of return to sport (87%) at a minimum of 3 years of follow-up⁶.

Important Tips:

- When the coracoid is retrieved through portal D (the inferolateral portal), there is a risk of stretching the musculocutaneous nerve.
- Trimming the coracoid graft could lead to stretching of the graft and the surrounding soft tissue, resulting in overstretching of the musculocutaneous nerve.
- To minimize the risk of musculocutaneous nerve injury, (1) the graft should be gently retrieved through portal D, (2) the graft should be trimmed with caution without overstretching it and surrounding soft tissue, and (3) a cannula should be utilized when driving the screw to fix the graft in order to avoid the surrounding soft tissue.

Acronyms & Abbreviations:

- RHD = right-hand dominant
- MRA = magnetic resonance angiography
- 3D-CT = 3-dimensional computed tomography
- PDS = polydioxanone suture
- MCN = musculocutaneous nerve

Lin Lin, MD, PhD¹

Hao Luo, MD¹

Xu Cheng, MD¹

Hui Yan, MD¹

Guoqing Cui, MD¹

¹Institute of Sports Medicine, Peking University Third Hospital, Beijing, People's Republic of China

Email for corresponding author: drcuiguqing1964@126.com

References

1. Casabianca L, Gerometta A, Masseurin A, Khiami F, Rousseau R, Hardy A, Pascal-Moussellard H, Loriaut P. Graft position and fusion rate following arthroscopic Latarjet. *Knee Surg Sports Traumatol Arthrosc*. 2016 Feb;24(2):507-12.
2. Zimmermann SM, Scheyerer MJ, Farshad M, Catanzaro S, Rahm S, Gerber C. Long-term restoration of anterior shoulder stability: a retrospective analysis of arthroscopic Bankart repair versus open Latarjet procedure. *J Bone Joint Surg Am*. 2016 Dec 7;98(23):1954-61.
3. Jeon YS, Jeong HY, Lee DK, Rhee YG. Borderline glenoid bone defect in anterior shoulder instability: Latarjet procedure versus Bankart repair. *Am J Sports Med*. 2018 Jul;46(9):2170-6.
4. Provencher MT, Ghodadra N, LeClere L, Solomon DJ, Romeo AA. Anatomic osteochondral glenoid reconstruction for recurrent glenohumeral instability with glenoid deficiency using a distal tibia allograft. *Arthroscopy*. 2009 Apr;25(4):446-52.
5. Warner JJ, Gill TJ, O'hollerhan JD, Pathare N, Millett PJ. Anatomical glenoid reconstruction for recurrent anterior glenohumeral instability with glenoid deficiency using an autogenous tricortical iliac crest bone graft. *Am J Sports Med*. 2006 Feb;34(2):205-12.
6. Lin L, Zhang M, Song Q, Cheng X, Shao Z, Yan H, Cui G. Cui's: Chinese Unique Inlay Bristow: A Novel Arthroscopic Surgical Procedure for Treatment of Recurrent Anterior Shoulder Instability with a Minimum 3-Year Follow-Up. *J Bone Joint Surg Am*. 2021 Jan 6;103(1):15-22.